


Prophylactic Clipping to Manage Potential Post-polypectomy Bleeding for Patients Using Antiplatelet Agents

technique spotlight



Arthur Yan, M.D.

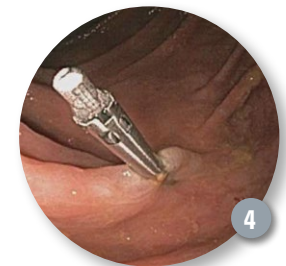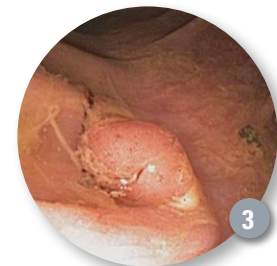
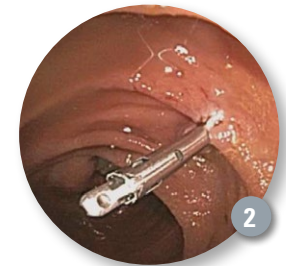
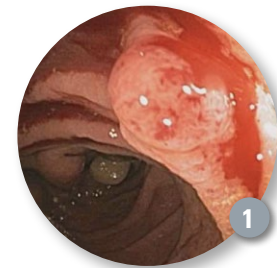
Core Gastroenterology
Exeter, New Hampshire,
USA

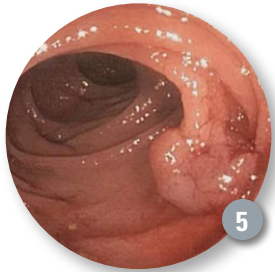Patient History

A 61-year-old male presented for a screening colonoscopy. He had an extensive cardiac history including type 2 diabetes, hypertension, hyperlipidemia, sick sinus syndrome with permanent pacemaker implantation, and coronary artery disease requiring placement of a drug-eluting stent seven years ago. He takes concomitant aspirin and clopidogrel, for which the latter has been held for seven days prior to the procedure. He denies any hematochezia, melena or abdominal pain. He has no family history of colonic neoplasms. His last colonoscopy was more than ten years ago for which he had an inadequate bowel preparation.

Procedure

The colonoscopy revealed small non-bleeding internal hemorrhoids, a normal terminal ileum, and diverticulosis extending from the ascending colon to the sigmoid colon. A total of six presumed adenomatous polyps were found during the procedure. One of these polyps in the ascending colon was friable on contact (Figure 1). The 7mm polyp was resected with a Captiflex™ Oval Snare using cautery. Given concurrent use of aspirin and clopidogrel and the risk for delayed post-polypectomy bleeding due to thermal injury in the right colon, a Resolution™ Clip was successfully deployed at the polypectomy site (Figure 2). A second 7mm polyp in the ascending colon was encountered (Figure 3). This was also resected with the Captiflex Oval Snare using thermal cautery, and followed by placement of a Resolution Clip (Figure 4). A third pedunculated polyp measuring 12mm was similarly resected and retrieved from the proximal

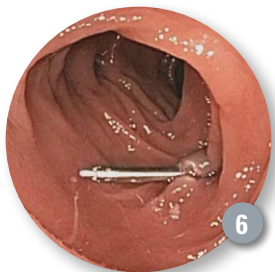



transverse colon with a Captiflex Oval Snare using electrocautery (Figure 5). A Resolution Clip was also placed the base of the polypectomy site (Figure 6).

Post Procedure

The patient resumed his clopidogrel that evening and continued to take his aspirin. The results from the pathology laboratory confirm the resected polyps to be tubular adenomas. No post-polypectomy bleeding was encountered. On one week follow-up, the patient reported feeling well with no melena or hematochezia.



Discussion

Delayed post-polypectomy bleeding can occur in up to 2% of patients, and is significantly higher in patients on dual antiplatelet agents. Post-polypectomy ulceration and thermal necrosis from electrocautery may injure the deeper layers of the colonic wall, resulting in delayed hemorrhage from blood vessels of the submucosa. The resection of large polyps as well as removal of polyps from the right colon can carry an increased risk of post-polypectomy hemorrhage. **As bleeding complications can occur anytime from one week to one month post-procedure, prophylactic placement of the Resolution Clip may help minimize this risk.**

Results from case studies are not predictive of results in other cases. Results in other cases may vary. All trademarks are property of their respective owners.

Indications, Contraindications, Warnings and Instructions for Use can be found in the product labeling supplied with each device.

CAUTION: Federal (USA) law restricts this device to sale by or on the order of a physician.

**Boston
Scientific**
Advancing science for life™

Boston Scientific Corporation
300 Boston Scientific Way
Marlborough, MA 01752-1234
www.bostonscientific.com

©2015 Boston Scientific Corporation
or its affiliates. All rights reserved.

ENDO-303909-AA April 2015