


technique spotlight

## Therapeutic Endoscopic Management of Synchronous Colon Lesions

**Charles Loewe, MD**

Center for Digestive Diseases, Sarasota, Florida



Open to the  
**Possibilities.™**



**Charles Loewe, MD**

Center for Digestive Diseases  
Sarasota, Florida

## Therapeutic Endoscopic Management of Synchronous Colon Lesions

### Introduction

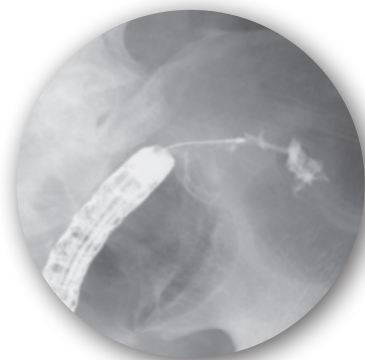Synchronous lesions of the colon may present a challenge when trying to determine treatment algorithms for patients. Studies have reported the incidence of synchronous colon lesions between 4-8%<sup>(1,2,3)</sup>, and if detected early, can often change the course of therapy that patients receive. The challenge for endoscopists is synchronous lesions are difficult to identify pre-operatively because the distal lesions prevent examination of any proximal lesions. CT Colonography has been helpful to identify proximal lesions.

### Case

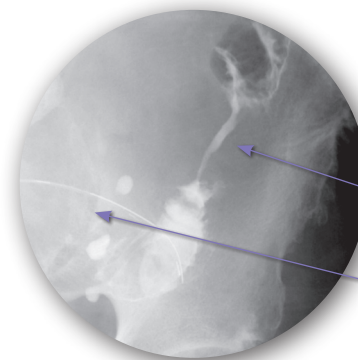
We report a case of an 86-year-old male who presented with a high grade stricture in the lower left quadrant at the junction of the descending colon and sigmoid. The patient was scheduled for a WallFlex Colonic Stent placement to decompress the colon in preparation for surgery. A double channel scope was utilized and advanced to the level of the stricture. A 450 Jagwire™

Guidewire was advanced through the stricture and a ball tip catheter was advanced over the guidewire. The catheter allowed for the injection of contrast to identify the appropriate length of the lesion (**Figure 1**).

Upon injection, a secondary lesion was noted and was consistent with a large bowel mucosal irregularity and the appearance of a malignant stricture (**Figure 2**).



**Figure 1**



**Figure 2**

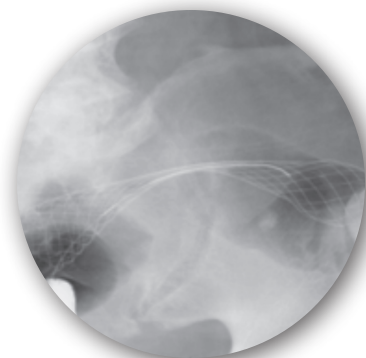
Lesion 2 visualized under fluoroscopy.

Scope seen at level of 1<sup>st</sup> lesion and passage of guidewire.

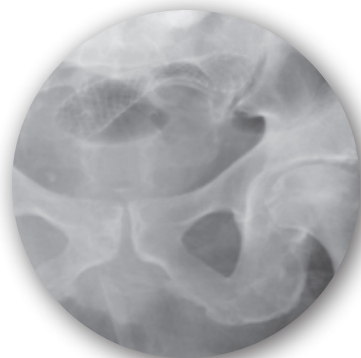
*(Continued)*

To allow optimal time for the WallFlex™ Colonic self-expanding metal stent (SEMS) to expand, a second stent procedure was scheduled 3 days later. In **Figures 3 and 4**, the compression of the stent from the primary colon lesion is observed; however the impact of the SEMS on the lesion, post-deployment, is observed 3 days later is

evident in **Figure 4**. In order for endoscopists to safely consider pre-operative colonoscopy or secondary stenting of synchronous lesions, Vitale and colleagues waited an average of 5 days (range 4-8) and completed the colonoscopy under fluoroscopy<sup>(4)</sup>.



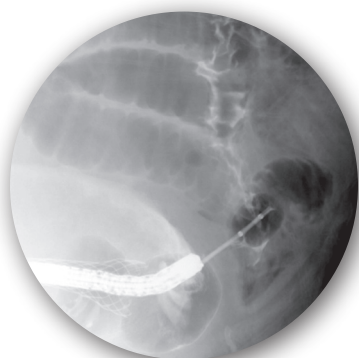
**Figure 3**



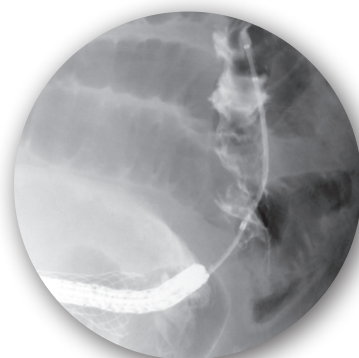**Figure 4**

In **Figures 5 and 6**, during the second procedure, the colonoscope is fluoroscopically seen inside the first stent. Similar techniques were used to traverse the synchronous lesion utilizing a double channel scope, 450 Jagwire™ Guidewire, contrast and a biliary extraction balloon.

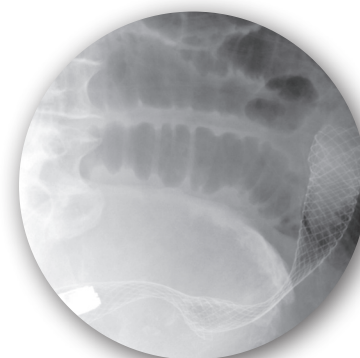
In **Figure 7** it is observed that both lesions have been traversed by SEMS. It is noted that the waste in the proximal second stent is consistent with a stricture.



**Figure 5**



**Figure 6**



**Figure 7**

## Recommendations

The management of acute colonic obstruction would benefit from a multi-disciplinary approach to achieve the optimal outcome for the patient, whether it is survival or palliation. Total large bowel evaluation, preferably using colonoscopy under fluoroscopy, is essential in patients

with cancer of the large bowel<sup>(4, 5)</sup>. The use of colonic stents to relieve colonic obstructions may allow for a more complete colon examination and identification of synchronous lesions.

## References

1. Vyas, J. J., Deshpande, R. K., Sharma, S. and Desai, P. B. (1983), Multiple primary cancers in Indian population: Metachronous and synchronous lesions. *J. Surg. Oncol.*, 23: 239–249. doi: 10.1002/jso.2930230406.
2. Sanna A. Mulder, Ries Kranse, Ronald A. Damhuis, Johannes H.W. de Wilt, Rob J.Th. Ouwendijk, Ernst J. Kuipers, Monique E. van Leerdam, Prevalence and prognosis of synchronous colorectal cancer: A Dutch population-based study, *Cancer Epidemiology*, Volume 35, Issue 5, October 2011, Pages 442-447, ISSN 1877-7821, 10.1016/j.canep.2010.12.007.
3. James M. Langevin, Santhat Nivatvongs, The true incidence of synchronous cancer of the large bowel: A prospective study, *The American Journal of Surgery*, Volume 147, Issue 3, March 1984, Pages 330-333, ISSN 0002-9610, 10.1016/0002-9610(84)90161-2. (<http://www.sciencedirect.com/science/article/pii/0002961084901612>)
4. Mario A. Vitale, Giuseppe Villotti, Lucia d'Alba, Stefano Frontespezi, Federico Iacopini, Giampaolo Iacopini, Preoperative colonoscopy after self-expandable metallic stent placement in patients with acute neoplastic colon obstruction, *Gastrointestinal Endoscopy*, Volume 63, Issue 6, May 2006, Pages 814-819, ISSN 0016-5107, 10.1016/j.gie.2005.12.032. (<http://www.sciencedirect.com/science/article/pii/S0016510706000162>)
5. Leandro Feo, David M Schaffzin Colonic stents: The modern treatment of colonic obstruction. *Advances in Therapy* (impact factor: 2.11). 01/2011; 28(2):73-86. DOI:10.1007/s12325-010-0094-6. Hahnemann University Hospital, Drexel University School of Medicine, Philadelphia, PA, USA.

**Boston  
Scientific**  
Advancing science for life™

Boston Scientific Corporation  
One Boston Scientific Place  
Natick, MA 01760-1537  
[www.bostonscientific.com/endo-resources](http://www.bostonscientific.com/endo-resources)

**Ordering Information**  
**1.888.272.1001**

©2013 Boston Scientific Corporation  
or its affiliates. All rights reserved.

ENDO-143405-AA 1M March 2013

Results from case studies are not predictive of results in other cases. Results in other cases may vary.

WallFlex and Jagwire are registered trademarks of Boston Scientific Corporation or its affiliates.

Indications, Contraindications, Warnings and Instructions for Use can be found in the product labeling supplied with each device.

**CAUTION: Federal (USA) law restricts this device to sale by or on the order of a physician.**