



OBSIDIO™ Conformable Embolic

Performance Testing

OBJECTIVE OF THE TESTS

Device safety was assessed by comparing the incidence of adverse events. The primary efficacy endpoint was the CT and angiographic absence of blood flow to the hypervascular tumor distal to the embolized artery. Complete absence of blood flow to the vascular distribution of the embolized artery was established as the criterion for success. The objectives were to demonstrate that Obsidio Embolic could be delivered safely, that Obsidio Embolic occludes the artery where it is deposited without migration, and that Obsidio Embolic does not lead to a change in standard blood tests, indicative of organ function or inflammation, or produce a fever or cause significant pain. A summary of the clinical study outcome is presented below.

STUDY DESIGN

The study was a single center study to evaluate the safety and performance of Obsidio Embolic in patients requiring vascular embolization in the pre-operative setting for the treatment of hypervascular tumors. Patients were treated between June 7 to June 11, 2021. The database for this reflected data collected through July 11 and included 4 patients. There was 1 investigational site (Vascular Interventional Radiology Department, Cerrahpasa Faculty of Medicine, Istanbul University). The study was sponsored and conducted by Alesphina Clinical Contract Research Organization (CRO), with the protocol approved by Institutional Review Board (IRB), the relevant federal regulations, and in compliance with applicable requirements in the GCP regulation regarding data from clinical investigations conducted outside the United States 21 CFR Part 812.28(1)). All subjects for this study were provided a consent form describing this study and providing sufficient information for subjects to make an informed decision about their participation in this study. Before a subject undergoes any study procedure, an informed consent discussion was conducted and written informed consent was obtained with the form signed by the subject.

Clinical Inclusion and Exclusion Criteria

Enrollment in the study was limited to patients who met the following inclusion criteria:

- Male or Female Subjects greater than or equal to 18 years of age.
- Subjects with confirmed finding of hypervascular tumor on CT and/or MRI for whom surgical resection is clinically indicated.
- Subject has been informed of the nature of the study and agrees to its provisions and has signed the Patient Informed Consent Form.
- Subject is willing and able to comply with protocol requirements, including all procedures, clinical evaluations, and follow-up visits.

Patients were not permitted to enroll in the study if they met any of the following exclusion criteria:

- Subject has ongoing adverse effects that may confound the evaluation of Obsidio Embolic.
- Subject is pregnant or Breast-Feeding, or female planning on becoming pregnant within the next 6 months.
- Subject has other concurrent conditions that in the opinion of the investigator would be unlikely to receive clinical benefit from the study procedure or participation in the study may compromise patient safety or study objectives (including but not limited to ongoing infection, renal dysfunction, morbid obesity).
- Subject has a known allergy or hypersensitivity to contrast media that cannot be adequately medicated.
- Subject is participating in another investigational research study investigating a device, drug, or procedure that has not completed the study treatment or that clinically interferes with these study endpoints.
- The lesion does not opacify on contrast enhanced CT or MR angiography study.
- The lesion does not appear hypervascular on catheter directed angiography.

Follow-up Schedule

After each embolization procedure, patients were referred to radiology department for a CT angiogram study with IV contrast. Upon completion of the CT study, patients were referred for surgery. Objective findings including imaging and laboratory test results (blood counts, liver/renal function) were collected. Medical device related adverse events and complications were recorded.

OBSIDIO™ Conformable Embolic

Clinical Endoints

The Primary Safety Endpoint is a composite endpoint that includes the incidence of:

- Serious Device-Related Adverse Events based on ISO 14155 adverse event definitions
- Serious Procedure-Related Adverse Events
- Non-Target Embolization

Events were reviewed and adjudicated by a physician staff member not involved in the study. Severity of complications were classified in accordance with Society of Interventional Radiology (SIR) Guidelines.

STUDY POPULATION DEMOGRAPHICS

The demographics for this type of study population are typical for a preoperative embolization study of hypervascular tumors performed in the US^{1,2}.

Mean Age was 54.4 years +/- 7.4 years with a median age of 57. All subjects were females. There were 4 kidney tumors. Tumors that received Obsidio Embolic embolization ranged in size from 2.4 cm to 14.7 cm in maximal diameter.

Table 1: Study Patient Summary

Patient	Tumor location	# of tumors	Size of tumor/s (cm)	# of embolization	Amount of Obsidio used (cc)	Surgical tumor resection
1	Left kidney lower pole	1	7.5 x 5.7 x 6.7	1	0.7	Day 1
2a	Right kidney mid-lower pole	1	10 x 8.4 x 9.1	1	0.7	Day 1
2b	Left kidney lower pole	1	2.3 x 2.4 x 1.9	1	0.3	Day 1
3	Left kidney mid-pole	1	2.6 x 2.4 x 2.4	1	0.7	Day 1
4	Left kidney mid-lower pole	1	14.7 x 11.4 x 11.3	1	1.7	Day 7

Upon enrollment, baseline CT angiogram study already available in the electronic medical records and in the PACS system was evaluated by the interventional radiology physician for each patient for complete characterization of the hypervascular tumor. Three (3) of the 4 patients underwent one embolization procedure. One patient, received embolization of a smaller tumor (2.3 x 1.9 cm) and another embolization in the contralateral kidney maximally measuring 10 x 9.1 cm. The smaller tumor was resected during a partial nephrectomy and the kidney with the larger tumor received nephrectomy. In 3 patients, the tumor was resected within 24 hours of the embolization procedure. In 1 patient, the surgical resection of the kidney was performed 7 days after the embolization procedure. The surgical resection was delayed due to difficulty in scheduling the surgery.

SAFETY AND EFFECTIVENESS RESULTS

Safety Results

The analysis of safety was based on the cohort of 4 patients that received 5 embolization procedures. The potential adverse events such as rupture/puncture of target vessel, unintended embolization, imaging abnormalities, stroke and death were monitored. No adverse event, attributed to the device, was reported. The potential technical complications such as vascular access complications, poor visualization of Obsidio Embolic, vasospasm, and catheter entrapment were monitored. No technical complications occurred.

Effectiveness Results

Primary endpoint success of achieving embolization was demonstrated by post procedure angiography. In all 5 patients, a 4 French guide catheter (Cook Medical) and a 2.8 Fr ProGreat microcatheter (Terumo) were used coaxially to catheterize the target vessels. Series of digital subtraction angiographies (DSA) were performed to characterize the blood supply of the hypervascular tumors. Through the microcatheter, the target arteries were catheterized and successfully embolized using 0.3 to 1.7 cc of Obsidio Embolic. See figures 1 through 5.

OBSIDIO™ Conformable Embolic

CONCLUSIONS

The primary study hypothesis that Obsidio Embolic could achieve absence of flow in the blood vessels of tumors was achieved. In one instance, Obsidio Embolic embolization was demonstrated to be durable without migration at day 7. The embolization procedure for this patient was performed on Thursday prior to the weekend and the operation was planned for the week after. There was no non-target embolization and no adverse events recorded; and, thus, safety endpoints were achieved.

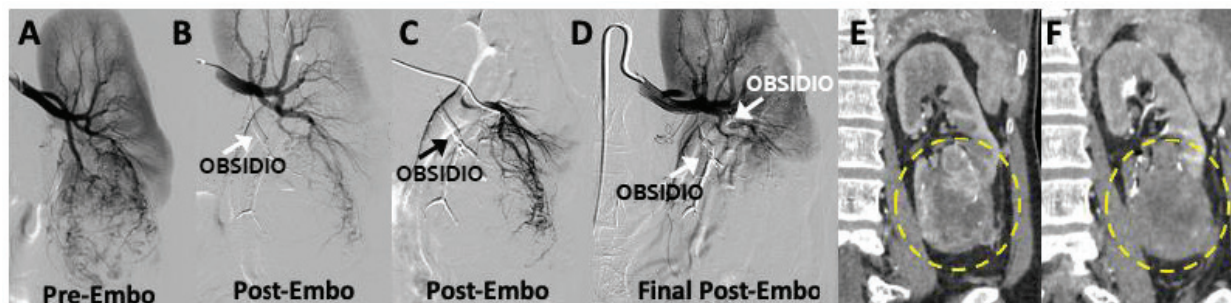


Figure 1: Patient 1.

Image A demonstrates a 7.5 x 5.7 x 6.7 cm hypervascular tumor in the lower of the left kidney. (B) The dominant arterial branch of the tumor was successfully embolized using Obsidio Embolic. The second major branch of the tumor was catheterized in C and embolized in D. Post-embolization DSA image in D demonstrates complete absence of perfusion of the hypervascular tumor. CT images E and F demonstrate a coronal view of the hypervascular renal tumor before (E) and after embolization with Obsidio Embolic (F) where there is no contrast enhancement visualized following embolization. The nephrectomy was performed the following day.

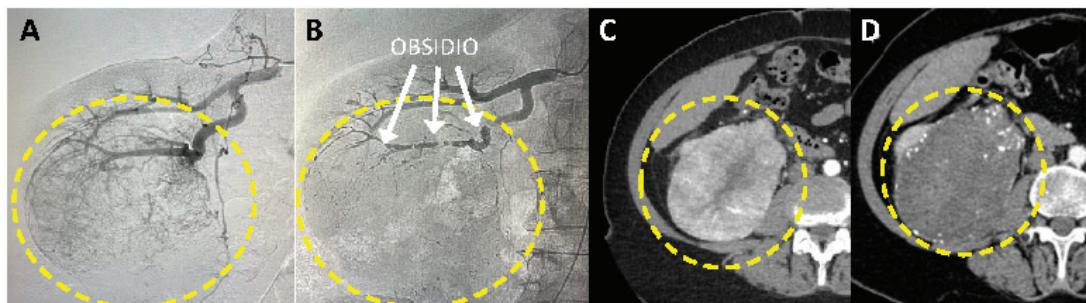


Figure 2: Patient 2.

Image A demonstrates a 10 x 8.4 x 9.1 cm hypervascular tumor in the mid to lower pole of the right kidney. (B) The dominant arterial branch of the tumor was successfully embolized using Obsidio Embolic (white arrows). CT images C and D demonstrate an axial view of the hypervascular renal tumor before (C) and after embolization with Obsidio Embolic (D) where there is no contrast enhancement visualized following embolization. The nephrectomy was performed the following day.

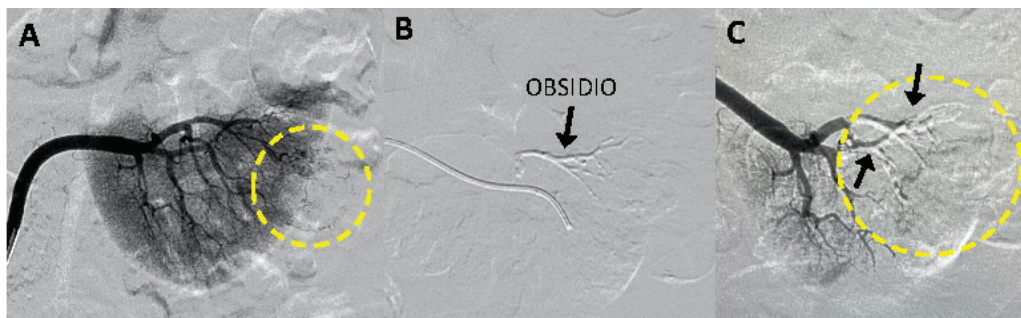


Figure 3: Patient 2.

Image A demonstrates a 2.3 x 2.4 x 1.9 cm hypervascular tumor in the lower pole of the left kidney (yellow dotted line). (B) The main arterial branch of the tumor was successfully embolized using Obsidio Embolic (arrow). (C) Following embolization of two dominant arterial branches that supply the tumor, DSA was performed which showed absence of any flow into tumor. The nephrectomy was performed the following day.

OBSIDIO™ Conformable Embolic

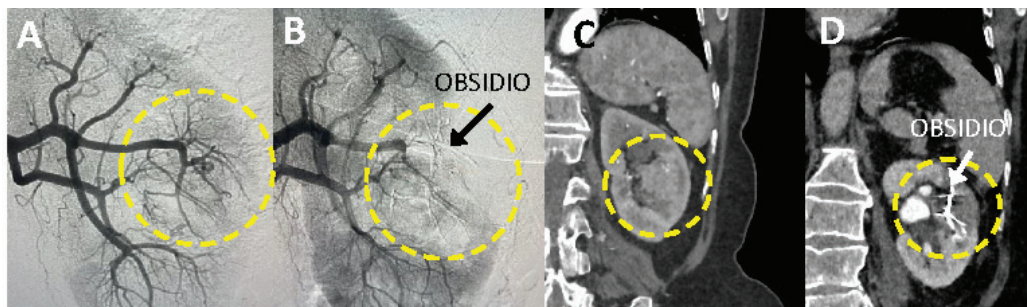


Figure 4: Patient 3.

Image A demonstrates a 2.6 x 2.4 x 2.4 cm hypervascular tumor in the mid-pole of the left kidney (yellow dotted line). (B) The main arterial branch of the tumor was successfully embolized using Obsidio Embolic (arrow). (C) CT images C and D demonstrate a coronal view of the hypervascular renal tumor before (C) and after embolization with Obsidio Embolic (D; white arrow) where there is no contrast enhancement visualized following embolization of the tumor. The nephrectomy was performed the following day.

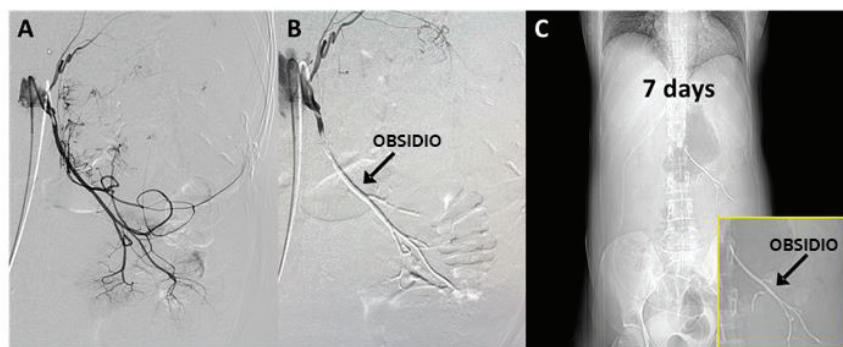


Figure 5: Patient 4.

Image A demonstrates a 14.7 x 11.4 x 11.3 cm hypervascular tumor in the left kidney. (B) The main arterial branch of the tumor was successfully embolized using Obsidio Embolic (arrow). (C) Abdominal X-ray at 7 days demonstrates a coronal view of the embolized artery (arrow); there is no difference in the position of Obsidio Embolic at the time of embolization procedure (B) and at day 7 (C). These images suggest that there is no evidence for Obsidio Embolic migration. The nephrectomy was performed at Day 7.

¹Muller, Arnaud, and Olivier Rouvière. "Renal artery embolization—indications, technical approaches and outcomes." *Nature Reviews Nephrology* 11.5 (2015): 288-301

²Shanmugasundaram, Srinidhi, et al. "Preoperative embolization of renal cell carcinoma prior to partial nephrectomy: A systematic review and meta-analysis." *Clinical Imaging* (2021).

OBSIDIO™ CONFORMABLE EMBOLIC

CAUTION: Federal (USA) law restricts this device to use by or on the order of a licensed physician.

INTENDED USE / INDICATIONS FOR USE: Obsidio Conformable Embolic is indicated for use in the embolization of: • Hypervascular tumors, • Blood vessels to occlude blood flow for controlling bleeding/hemorrhaging in the peripheral vasculature. **CONTRAINDICATIONS:** • Patients with a known hypersensitivity to porcine products • Patients intolerant to occlusion procedures • Vascular anatomy or blood flow that precludes catheter placement or embolic agent injection, such as: • Presence or likely onset of vasospasm • Presence of severe atheromatous disease • Presence of collateral vessel pathways potentially endangering non-target vascular territories during embolization -Presence of arteries supplying the lesion not large enough to accept the selected device -Vascular resistance peripheral to the feeding arteries precluding passage of the product • Arteriovenous shunts (i.e., where the blood does not pass through an arterial/capillary/venous transition but directly from an artery to a vein) • Presence of patent extra-to-intracranial anastomoses or shunts • Presence of end arteries leading directly to cranial nerves • Use in the pulmonary, coronary, and intracerebral vasculature • Use in any vasculature where the product could pass directly into the internal carotid artery, vertebral artery, intracranial vasculature **WARNINGS:** • Performing therapeutic embolization to occlude blood vessels is a high-risk procedure. Perform the procedure only under the direction of personnel with vascular embolization experience and thorough knowledge of angiographic techniques. • Obsidio Embolic contains gelatin of porcine origin, and therefore, could cause an immune reaction in patients who are hypersensitive to collagen or gelatin. Careful consideration should be given prior to using this product in patients who are suspected to be allergic to injections containing gelatin. • As with any embolization device, non-target embolization such as due to arterial-venous shunting, or undesirable reflux or passage of Obsidio Embolic into non-target arteries adjacent to the targeted lesion or through the lesion into other arteries or arterial beds of systemic, pulmonary, or coronary circulations, may potentially lead to significant complications. • Extreme caution should be used for any procedures involving the extracranial circulation encompassing the head and neck. The physician should carefully weigh the potential benefits of using embolization against the risks and potential complications of this procedure, which may include blindness, hearing loss, loss of smell, paralysis and death. • Avoid embolization near branch points as this may increase the risk of non-target embolization. • Pay careful attention for signs of non-targeted embolization. During injection carefully monitor patient vital signs to include SpO₂ (e.g., hypoxia, central nervous system changes). Consider terminating the procedure and investigating for possible shunting if non-target embolization is suspected or patient symptoms develop. • Post embolization swelling may result in ischemia to tissue adjacent to target area. Care must be given to avoid ischemia intolerant, nontargeted tissue such as nervous tissue. **PRECAUTIONS:** • Additional evaluations or precautions may be necessary in managing periprocedural care for patients with conditions such as, but not limited to bleeding diathesis or hypercoagulable state and immunocompromise. **POTENTIAL COMPLICATIONS:** Vascular embolization is a high-risk procedure. Complications may occur at any time during or after the procedure, and may include, but are not limited to, the following: • Paralysis resulting from non-targeted embolization • Ischemic injury from adjacent tissue edema • Undesirable reflux or passage of Obsidio Embolic into non-target arteries adjacent to the targeted lesion or through the lesion into other arteries or arterial beds of systemic circulation or, pulmonary, or coronary circulations, resulting in non-target embolization • Pulmonary embolism and/or stroke due to arterial-venous shunting, for example from a patent-foramen-ovale • Ischemia at an undesirable location including ischemic stroke, ischemic infarction (including myocardial infarction), and tissue necrosis • Capillary bed occlusion and tissue damage, which may lead to abscess formation and sepsis • Vessel or lesion rupture and hemorrhage • Recanalization • Foreign body reactions necessitating medical intervention • Infection necessitating medical intervention • Complications related to catheterization (e.g., hematoma at the site of entry, clot formation at the tip of the catheter and subsequent dislodgment, and nerve and/or circulatory injuries, which may result in leg injury) • Allergic reaction to medications (e.g., analgesics), contrast media or embolic material • Pain and/or rash, possibly delayed from the time of embolization • Death • Neurological deficits, including cranial nerve palsies/injury (e.g., blindness, hearing loss, loss of smell and/or paralysis) • Additional information is found in the Warnings section **PI_1473303_AA**

Results from case studies are not necessarily predictive of results in other cases. Results in other cases may vary. All trademarks are the property of their respective owners.

Boston Scientific
Advancing science for life™

Peripheral Interventions
300 Boston Scientific Way
Marlborough, MA 01752-1234
www.bostonscientific.com

To order product or for more information
contact customer service at 1.888.272.1001.

© 2023 Boston Scientific Corporation or its affiliates. All rights reserved.

PI-1491905-AA